



**PRESENTING CLINICAL SIGNS**

History: Grade 2/6 murmur. Pre-anesthetic evaluation (spay).

**DATE**

1/6/23

**ECHOCARDIOGRAPHIC FINDINGS**

2D, M-mode, and Doppler study.

**PERFORMED BY:**

Kelly Vazquez

**INTERPRETED BY**

Keith Blass, DVM,  
MS, DACVIM  
(Cardiology)

Left atrial size is normal. The mitral valve is normal. Left ventricular wall thickness is normal. Left ventricular dimensions are normal. Left ventricular systolic function is hyperdynamic. The aorta and aortic valve appear normal, though there is mildly increased flow velocity in the ascending aorta. Right atrial and right ventricular dimensions are normal. The tricuspid valve appears normal, though trace tricuspid regurgitation is present. The pulmonary artery and pulmonic valve appear normal, though trace pulmonic insufficiency is present. No heartworms are visualized. No shunting lesions are visualized. No pericardial effusion or cardiac masses are seen.

**PATIENT**

Crystal Lasiw

LA - 40.0 mm  
IVSd - 10.4 mm  
LVPWd - 10.8 mm  
LVIDd - 36.6 mm  
LVIDs - 19.6 mm  
FS - 46%  
RA - 32.6 mm  
LVOT - 2.03 m/s  
RVOT - 1.35 m/s

**SPECIES**

Canine

**BREED**

Golden Retriever

**ASSESSMENT/RECOMMENDATIONS**

Crystal's murmur appears to be due to the presence of mildly increased flow velocity in her aorta. As the flow is laminar and Crystal is already 10 months old with a velocity below 2.5 m/s, it appears that this represents a functional/innocent increased in flow velocity rather than the presence of subaortic stenosis (SAS).

No therapy is recommended based on this exam, and there are no contraindications to general anesthesia or the use of any specific anesthetic agents.

**SEX**

FI

A recheck echocardiogram can be considered in 6 months to make sure that Crystal's aortic flow is still consistent with a functional/innocent velocity increase when she is fully grown.

**AGE**

10 mo

**WEIGHT**

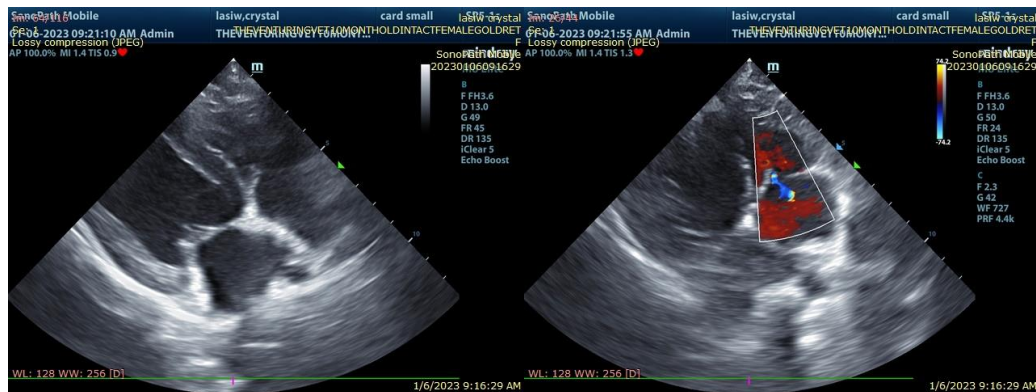
73 lb

**HOSPITAL NAME**

The Venturing Vet

**REFERRING VET**

Dr. Herzog





DATE

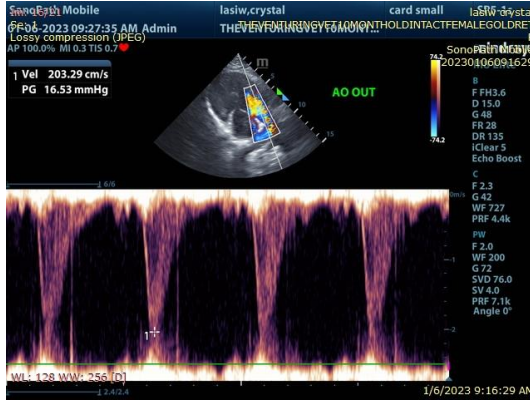
1/6/23

PERFORMED BY:

Kelly Vazquez

INTERPRETED BY

Keith Blass, DVM,  
MS, DACVIM  
(Cardiology)



The information and recommendations provided are based on the images presented by the referring veterinarian. No evaluation can be communicated regarding pathology that was not visible in the image/video clips provided.

Thank you for this referral. If the clinical or image interpretation does not parallel your findings or if I can be of any further assistance please contact me.

PATIENT

Crystal Lasiw

Keith Blass, DVM, MS, DACVIM (Cardiology)  
KeithBlass@gmail.com  
631-804-5754

SPECIES

Canine

BREED

Golden Retriever

SEX

FI

AGE

10 mo

WEIGHT

73 lb

HOSPITAL NAME

The Venturing Vet

REFERRING VET

Dr. Herzog